

Safety and Efficacy of 5% Imiquimod Cream for the Treatment of Skin Dysplasia in High-Risk Renal Transplant Recipients

Randomized, Double-blind, Placebo-Controlled Trial

Victoria L. Brown, MRCP; Catherine L. Atkins, MSc; Lucy Ghali, PhD; Rino Cerio, FRCPATH; Catherine A. Harwood, MRCP, PhD; Charlotte M. Proby, MA, FRCP

Objective: To evaluate the safety and efficacy of 5% imiquimod cream for cutaneous dysplasia in high-risk renal transplant recipients.

Design: A randomized, blinded, placebo-controlled study comparing treated with control skin.

Setting: A specialist organ transplant dermatology clinic.

Patients: Twenty-one high-risk patients with skin cancer with comparable areas of clinically atypical skin on dorsal hands or forearms.

Interventions: Imiquimod or placebo (randomly assigned) applied 3 times a week for 16 weeks to 1 dorsal hand or forearm, with 8 months of follow-up. At week 16, biopsy samples were collected from preassigned sites in the treatment and control areas and were examined for dysplasia.

Main Outcome Measures: The proportion of patients showing reduced numbers of viral and keratotic

lesions and reduced histological severity of dysplasia in the treatment vs control areas at week 16, serum creatinine levels, and tumors developing in the study sites.

Results: Fourteen patients receiving imiquimod and 6 receiving placebo completed the study. Seven patients using imiquimod (1 taking placebo) had reduced skin atypia, 7 using imiquimod (none taking placebo) had reduced viral warts, and 5 using imiquimod (1 taking placebo) showed less dysplasia histologically. In 1 year, fewer squamous skin tumors arose in imiquimod-treated skin than in control areas. Renal function was not adversely affected.

Conclusions: Topical 5% imiquimod cream seems to be safe on skin areas up to 60 cm² in renal transplant recipients. It may be effective in reducing cutaneous dysplasia and the frequency of squamous tumors developing in high-risk patients. Larger studies are required to confirm these results.

Arch Dermatol. 2005;141:985-993

Author Affiliations: Centre for Cutaneous Research and Department of Dermatology, Barts and The London School of Medicine & Dentistry, Queen Mary, University of London (Drs Brown, Cerio, Harwood, and Proby and Ms Atkins), and Cancer Research UK Skin Tumour Laboratory (Drs Ghali, Harwood, and Proby), London, England.

Financial Disclosure: Dr Proby has given expert advice to 3M Health Care Ltd, Loughborough, Leicestershire, England, for which she has received honorarium.

IMMUNOSUPPRESSED RENAL TRANSPLANT recipients (RTRs) experience significant morbidity from cutaneous viral warts (VWs), actinic keratoses (AK), Bowen disease (carcinoma in situ [CIS]), cutaneous squamous cell carcinoma (SCC), and basal cell carcinoma (BCC). Owing to the lifelong requirement for immunosuppression in RTRs, these skin abnormalities tend to be difficult to treat, with their multiplicity of lesions, frequent recurrences, and resistance to many treatment modalities.¹ This treatment difficulty applies particularly to a high-risk group of immunosuppressed patients in whom a "field change" of skin abnormality occurs on sun-exposed sites, within which VWs,

AKs, and other premalignant cutaneous lesions commonly arise on a background of histological dysplasia. These areas of field change have high malignant potential and account for much of the cutaneous-related morbidity and mortality seen in this population.

A new chemotherapeutic agent is required for these patients, and one possible candidate is imiquimod (Aldara; 3M Pharmaceuticals, St Paul, Minn). Imiquimod is a member of a novel class of synthetic immune response modifiers that has antiviral and antitumor activity. Imiquimod binds to toll-like receptor 7,² which activates dendritic cells, macrophages, and monocytes to synthesize and release a variety of different proinflammatory

tory cytokines that modulate innate and acquired cellular immune responses.³ The final result is the generation of cytotoxic effector T cells and a T-helper type 1 immune response. This has been shown to be the mechanism of imiquimod-induced VW regression.⁴ Imiquimod-associated antitumor responses also involve the induction of apoptosis, as shown in SCC cell lines⁵ and superficial BCC in vivo.^{5,6} The mechanisms by which imiquimod may directly induce apoptosis in tumor cells have not been fully elucidated to date, but a reduction in the expression of the antiapoptotic protein Bcl-2 is reported.⁶

In immunocompetent patients, imiquimod has been shown to successfully treat genital VWs,⁷ BCC,⁸⁻¹⁰ cutaneous VWs,¹¹ AKs,^{12,13} and Bowen disease.¹⁴ In addition, 2 recent case reports^{15,16} show clinical and histological cure of invasive cutaneous SCC after treatment with imiquimod. All these skin lesions are frequently seen in RTRs, and the results of imiquimod used to treat these conditions in the immunocompetent population are encouraging for its putative application in RTRs. Furthermore, there is some evidence that human papillomavirus may play a role in the etiology of nonmelanoma skin cancer, in particular cutaneous SCC.¹⁷ In RTRs, therefore, imiquimod may exert a dual beneficial effect, eradicating VWs and human papillomavirus-infected premalignant and malignant skin lesions.

Imiquimod is attractive in the context of organ transplantation owing to its activation of the local cutaneous immune system. However, in the setting of systemic iatrogenic immunosuppression used to prevent graft rejection, imiquimod may not be able to generate the immune response necessary for its antiviral and antitumor effects. Equally important was to address the safety of a topical immunostimulant in a patient with an allograft.¹⁸

Most previous studies that examined imiquimod efficacy have included only immunocompetent individuals. Occasional uncontrolled small case series and individual reports are published of successful treatment of cutaneous VWs,¹⁹⁻²¹ molluscum contagiosum,^{22,23} Bowen disease,²⁴ and BCCs²⁵ in immunosuppressed individuals (human immunodeficiency virus-positive and organ transplant patients).

This article reports the first randomized, double-blind, placebo-controlled trial in 21 immunosuppressed RTRs, with the primary objective of assessing the safety and efficacy of 5% imiquimod for the treatment of cutaneous dysplasia in this patient group. A secondary objective is to assess the rate of development of new carcinomas in imiquimod-treated skin compared with control areas. The accelerated skin carcinogenesis seen in RTRs makes them the ideal population in which to evaluate the potential of immune response modifiers as chemopreventive agents.

METHODS

Patients were recruited to the study from a dedicated skin organ transplant and immunosuppression clinic at Barts and The Royal London Hospital between January 30, 2001, and October 2, 2002. Written informed consent was obtained from the

patients and their renal physicians. Approval for the study was obtained from the East London and The City Health Authority Research Ethics Committee. Patients aged 18 to 80 years were included if they satisfied all of the following criteria:

1. Immunosuppressed RTRs at high risk for skin cancer as determined by skin type (fair), high previous sun exposure (outdoor occupation or hobby, sunny holidays abroad, or living overseas for at least 6 months), and time since transplantation (≥ 5 years)
2. One or more biopsy samples showing histologically confirmed invasive SCC or CIS, with clinical evidence of dysplastic skin.
3. A minimum of 2 areas of equivalent bilateral involvement (assessed visually) on the dorsal forearms or hands with warty keratoses or other premalignant skin lesions.
4. Stable renal function with no cause for clinical concern regarding possible allograft rejection.

Patients were instructed not to use any topical chemopreventive (eg, fluorouracil cream) or topical immunomodulatory treatment at any body location during a "washout" period of 4 weeks before study entry.

During the 1-year study, no concomitant medication or treatment at the study drug treatment site or untreated control site was permitted. No other investigational drugs or oral antiviral medications were permitted in the 4 weeks preceding study entry and throughout treatment and follow-up. All patients received standard advice to use a sun protection factor sunscreen of at least 15 on all sun-exposed skin, including the study and control areas.

STUDY POPULATION

Twenty-one patients were recruited (10 men and 11 women). Baseline demographic and clinical characteristics of these patients are given in **Table 1**. Their mean age at study entry was 56 years (range, 32-71 years), with a mean of 18 years since kidney transplantation (range, 7-30 years). Immunosuppressive drug regimens are detailed in Table 1.

Four patients were also taking low-dose acitretin (10-30 mg daily) as chemoprophylaxis against further SCC (Table 1). The dose of acitretin in all patients had been stable for at least 12 months before study entry and was not altered during treatment or follow-up. Three of these 4 patients had continued to develop 2 to 7 SCCs per year in the 4 years preceding study entry, and, therefore, acitretin had failed to provide complete chemoprophylaxis. In the fourth patient there was a reduction in the number of tumors after the introduction of acitretin 4 years previously; however, she continued to have AKs and 1 SCC preceding study entry.

STUDY DESIGN

Patients were randomized in a 2:1 ratio to receive active agent vs placebo, and the investigators and the patients were masked to the treatment received. At the initial visit, 2 clinically similar areas of 20 to 60 cm² (1 on either limb) were chosen on the dorsum of the hand or forearm: 1 for treatment with the study drug and the other (on the opposite limb) as an untreated control area. Both areas were photographed, and the number and type of skin lesions were mapped onto a printed diagrammatic template. Equivalent areas of skin abnormality in the treatment and control sites were chosen for punch biopsy examination at week 16, and the results were mapped precisely on the template at study initiation to reduce the risk of bias.

The study creams were supplied in similarly packaged single-dose sachets (each containing 250 mg of either 5% imiquimod

Table 1. Baseline Demographic and Clinical Characteristics of the 21 Study Patients

Patient No./Sex/Age, y	Years Since Transplantation	Immunosuppressive Drugs Used	Acitretin Use (Duration, mo)	Previous NMSCs, No.		
				SCC	CIS	BCC
1/F/45	26	P, A	No	5	1	1
2/M/67	16	P, A	Yes (87)	24	5	2
3/F/54	18	A, C	No	1	6	0
4/F/60	17½	P, A	Yes (58)	4	3	0
5/F/67	19	P, A	No	4	0	0
6/M/51	20	P, A	No	4	0	2
7/F/71	8	P, A, C	No	16	2	1
8/M/56	17½	P, C	No	5	2	0
9/F/68	25	P, A, C	No	3	0	0
10/F/42	13½	P, A, C	No	15	6	2
12/M/32	15	P, M	No	6	0	0
13/F/46	23	P, A	No	2	1	0
14/F/67	26	P, A	No	0	1	4
16/M/51	12½	P, A, C	Yes (24)	3	1	8
17/F/65	18	A, C	No	2	1	3
18/F/48	7	P, A, C	No	2	0	0
19/M/67	7½	P, A, C, M	Yes (66)	4	1	2
20/M/43	14	P, C	No	1	0	0
21/M/61	30	P, A	No	0	1	2
22/M/68	20½	P, A	No	1	0	1
23/M/59	13½	P, C, M	No	0	1	0

Abbreviations: A, azathioprine; BCC, basal cell carcinoma; C, ciclosporin; CIS, carcinoma in situ/Bowen disease; M, mycophenolate mofetil; NMSCs, nonmelanoma skin cancers; P, prednisolone; SCC, squamous cell carcinoma.

cream [12.5 mg of active ingredient] or matching placebo cream) such that neither the patient nor the clinician was aware of the contents of the sachets. The study cream was applied to the study area 3 times per week for 16 weeks or until all lesions cleared at the application site. Study cream was applied at night and remained on the skin for at least 8 hours before being washed off. Patients were provided with a diary card for recording applications of the cream and adverse events.

Efficacy was evaluated at baseline and at weeks 8 and 16 by detailed clinical mapping of the number and type of lesions (VWs, AKs, and field change areas) on the application and control areas, with photographic monitoring. Any adverse events were assessed and noted by the investigating clinician (V.L.B.) at weeks 2, 4, 8, 12, and 16. Specifically, local skin reactions were graded on a scale from 0 to 3 (0 indicates none; 1, mild; 2, moderate; and 3, severe) for erythema, edema, induration, vesicles/pustules, erosion/ulceration, excoriation/flaking, and scabbing for the application and control sites separately, with a maximum score of 21. The patients independently noted any local toxic effects on their diary card. A rest period of up to 7 days was permitted if a severe local skin reaction developed (defined as a local skin reaction that substantially interferes with normal daily activities). Safety with reference to the kidney allograft was evaluated by measuring serum creatinine levels weekly for 4 weeks, then every 2 to 4 weeks until the end of the 4-month treatment period and every 4 to 8 weeks during the 8 months of follow-up.

At week 16, punch biopsy samples were collected from the 2 areas chosen at baseline. These samples were assessed by a dermatopathologist (R.C.) who was blinded to the treatment applied and who had no knowledge of which was the application vs the control site for each patient. Inflammation and dysplasia were graded as absent, mild, moderate, or severe.

After 4 months of treatment, patients were reviewed every 4 to 8 weeks for another 8 months. Any clinically suspicious lesions that arose on either the treatment or control sites during the 1-year study were photographed, excised, and assessed histologically.

Using standard immunohistochemical techniques, CD4 and CD8 expression was examined to assess the inflammatory infiltrate, CD68 expression was examined as a macrophage marker, and p53 expression was also assessed. In brief, 4-µm transverse sections of paraffin-embedded tissue were cut onto electrostatically charged glass slides (Superfrost Plus; Erie Scientific Co, Portsmouth, NH), deparaffinized, and then immersed in 3% hydrogen peroxide in methanol to quench endogenous peroxidases. Antigen retrieval was achieved by microwaving the slides for 18 minutes (8 minutes to boiling and 10 minutes at boiling) using 0.01M citrate buffer (pH 6.0). Sections were incubated in the primary monoclonal antibody (CD4 or CD8: Dako Ltd, Cambridgeshire, England; CD68 [PGM1] and p53: DakoCytomation, Cambridgeshire) for 1 hour at room temperature. Normal appendix tissue was used as control for CD68, breast carcinoma for p53. All washes were performed in Tris-buffered saline, pH 7.6, and then incubated in a secondary biotinylated antibody (Vectastain Universal Elite ABC kit; Vector Laboratories, Peterborough, England) at room temperature for 30 minutes and further rinsed in Tris-buffered saline. A tertiary peroxidase-labeled avidin-biotin complex was applied at room temperature for 30 minutes before developing with diaminobenzidine (Bio Genex, San Ramon, Calif). All slides were counterstained with Gills hematoxylin (Sigma-Aldrich Co Ltd, Dorset, England) and dehydrated in a series of alcohols before being mounted in a nonaqueous mounting media.

Immunohistochemical findings were scored as follows: negative (-), 1 to 50 positive cells per high-power field (+), 51 to 100 positive cells per high-power field field (++) and greater than 100 positive cells per high-power field (+++). Scores were compared in study vs control biopsy samples and were recorded as follows: 0, no difference between study and control areas; 1, increased in study area compared with control; 2, greatly increased in study area compared with control; or -1, reduced in study area compared with control. The Fisher exact test was used to assess statistical significance in all cases.

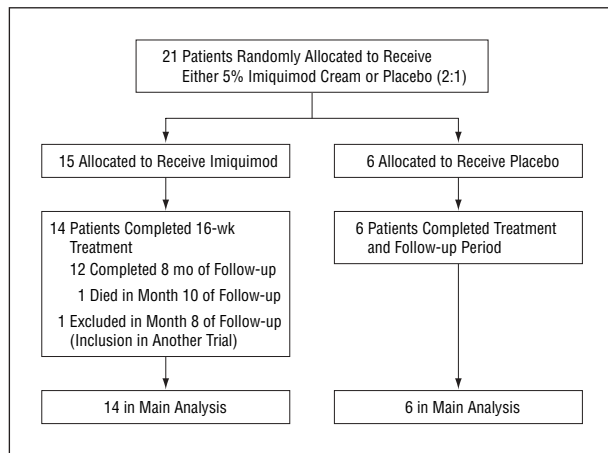


Figure 1. Flow of the participants at each stage of the study.

RESULTS

Twenty (95%) of 21 patients completed the 16 weeks of treatment. The progress of each patient is shown in **Figure 1**. Of the 20 patients, 14 received active treatment and 6 received placebo cream. None of the participants had any change in their immunosuppressant drug regimens during the 16-week treatment period. Patient 9 died in week 3 of the treatment phase of a brachial artery embolus and is excluded from the study analysis. Patient 19 died in the 10th month of follow-up because of complications arising from a spinal injury after a fall. Although both patients who died had received active cream, no connection could be established between their deaths and their use of imiquimod cream. Patient 5 was excluded from the study in the 8th month of follow-up owing to her inclusion in another trial to assess a new chemotherapeutic agent to treat a relapse of multiple myeloma.

SAFETY

None of the patients receiving active treatment experienced any detrimental effect on their renal allograft. Mean serum creatinine levels during the 16-week treatment period were compared with mean values 12 months before the study and during the 8 months after treatment (ie, after week 16). A percentage change during the study was calculated by comparing the mean serum creatinine value in weeks 12 to 16 with the prestudy mean value (**Table 2**). In many patients (in both groups), this value was found to fluctuate by up to 10% above and below baseline (Table 2). No patient showed more than a 20% increase in serum creatinine concentration during the 16 weeks of treatment. Overall, these data suggest that imiquimod treatment to a limited area of skin does not have an adverse effect on renal function in RTRs.

EFFICACY

Clinical and histological assessments at weeks 0 and 16 are given in Table 2. Seven of 14 patients receiving active treatment and 1 of 6 taking placebo had a reduction

in the areas of field change as assessed clinically ($P = .32$), whereas 5 of 14 imiquimod-treated and 1 of 6 placebo-treated patients had reduced numbers of keratoses ($P = .61$). On histological assessment of the week 16 biopsy samples, 5 of 14 treated patients (1 of 6 taking placebo) had reduced dysplasia in the study hand compared with the control hand ($P = .61$). There was also a reduction in the number of plane VWs in 7 of 14 patients receiving active treatment and in none of 6 taking placebo ($P = .05$) (Table 2). Patient 1, who showed a reduction in keratoses, dysplasia, and warts, is shown in **Figure 2**.

LOCAL ADVERSE EVENTS

Clinically apparent inflammation occurred in only 5 patients (4 receiving active treatment and 1 taking placebo), with symptoms first noted at 4, 6, 8, 12, and 16 weeks, respectively. Symptoms included erythema in 4 patients, erosions or superficial ulceration in 5, scabbing in 5, and induration in 1. An example of local inflammation on the treatment hand of patient 5 is shown in **Figure 3**. Patient 16 had symptoms severe enough (score, 11 of 21) to necessitate a 2-week discontinuation of the drugrest in weeks 10 and 11. Histological evidence of inflammation was apparent in study biopsy samples from 5 patients (4 receiving active treatment and 1 taking placebo) but did not always correlate with clinical inflammation. Some sampling bias is probable (see the "Study Limitations" subsection), but also the inflammation had subsided by the time biopsy samples were collected for patient 1 (who showed the greatest clinical benefit) and for patient 16 (who required the 2-week rest). In this small series, there was no significant correlation between beneficial clinical response and the degree of inflammation (Table 2).

CHEMOPROPHYLAXIS

No malignancy developed on imiquimod-treated skin during the active treatment phase of the study, whereas 1 tumor developed on placebo-treated skin and 2 tumors developed on control skin of patients in the active treatment group during the 4-month treatment period (**Table 3**). During follow-up, patient 16 developed 2 CISs on imiquimod-treated skin, at 8 and 12 months. These were the only tumors to arise on imiquimod-treated skin during the 12-month study. In comparison, 4 patients (including patient 16) developed invasive SCC ($n = 2$) or CIS ($n = 2$) on the untreated control skin (Table 3). Thus, in the imiquimod-treated group, 1 of 14 patients developed carcinoma in imiquimod-treated and control skin vs 3 of 14 patients with tumors on control skin only (Table 3). In the placebo-treated group, 1 of 6 participants developed SCC on placebo-treated and control skin, 1 developed SCC on placebo-treated skin only, and 1 developed SCC on control skin only (Table 3). These patient and tumor numbers are too small to provide meaningful statistical analysis. No patient developed a BCC at either control or treatment sites during the study, although 1 tumor was pathologically defined as a basalioid SCC.

Table 2. Study Results

Patient No.	Serum Creatinine, % Change*	Clinical Variables†						Assessment of Inflammation‡				Histological Assessment of Dysplasia§	
		Viral Warts		Keratoses		Areas of "Field Change"		Clinical		Histology		S	C
		S	C	S	C	S	C	S	C	S	C		
Imiquimod-Treated Group													
1	-15.4	-	-	-	+	-	+/-	++	+	0	1	0	1
2	+7.9	+	+	+	+	+	+/-	+	+	1	1	2	0
4	-10.1	+	-	+/-	+/-	+/-	+/-	++	0	3	0	1	0
5	+19.6	+	+	+/-	+	-	+/-	++	0	2	0	0	1
8	+13.2	+	+	+	-	+	+	+	+/-	1	1	1	0
10	-2.7	-	+	+/-	+	+	+	0	+	1	1	1	2
12	-0.1	-	+	+	+	+	-	+	+	1	0	0	0
14	+9.4	-	+	-	+	-	+/-	+	0	1	1	0	0
16	-3.2	-	+	-	+/-	-	+/-	++	0	0	1	0	2
17	-9.1	+	-	-	-	+	-	+	+	0	1	2	0
19	+0.8	-	+	-	+	-	+/-	+	0	2	1	3	2
20	-2.1	+	+	+/-	-	-	+/-	+	0	1	0	2	2
22	-6.3	-	+	-	+	-	+/-	+	+	1	2	0	SCC
23	-3.4	+	+	+/-	+	+/-	+/-	0	0	2	1	1	1
Placebo-Treated Group													
3	-3.1	+	+	+/-	+/-	+/-	+/-	+	+	1	2	0	1
6	+9.7	+	+	+	+/-	+	+	0	0	0	1	1	1
7	-9.7	+	+	+	+	+/-	-	+/-	+/-	0	1	0	0
13	-1.8	+	+	+	+	+/-	+/-	+	+	0	NE	1	NE
18	+1.2	+	+	-	+	-	+	++	0	3	0	CIS	2/3
21	-4.9	+	+	+/-	+	+/-	+	+	+	1	2	2	2

Abbreviations: C, control area; CIS, carcinoma in situ; NE, not evaluable/not evaluated; S, study area; SCC, squamous cell carcinoma.

*Percentage change in serum creatinine level from mean prestudy levels to mean levels measured during weeks 12 to 16.

†Numbers of lesions (extent of field change) in the study and control areas were compared at the start and end of treatment (weeks 0 and 16, respectively). Minus indicates a reduction in numbers/extent; plus/minus, no change in numbers/extent; and plus, an increase in numbers/extent.

‡Clinical assessment of inflammation was noted as severe (++), moderate (+), mild (+/-), or absent (0). Histological assessment of inflammation was graded as none (0), mild (1), moderate (2), or severe (3).

§Dysplasia was assessed histologically in biopsy samples collected from study areas (treated) and control areas (untreated) at week 16. Dysplasia was graded as none (0), mild (1), moderate (2), severe (3), CIS, or SCC.

PATIENTS TAKING ACITRETIN

All 4 patients who were taking systemic acitretin as chemoprophylaxis before and throughout the study were randomized to receive imiquimod treatment. Two of these 4 patients (patients 4 and 16) developed clinical evidence of inflammation during the treatment phase. Patient 16 developed 3 CISs on control and study sites during the 12-month period (Table 3). The other 3 patients (patients 2, 4, and 19) developed tumors (SCC and BCC) during the 12-month study, but none within the study or control areas.

IMMUNOHISTOCHEMICAL ANALYSIS

In most of the imiquimod-treated biopsy samples (9 of 14), there was an increase in CD68 expression in study skin compared with control skin, but this increase was associated only with clinical and histological improvement in dysplasia in 5 of 9 patients (Figure 4). Four of 5 patients who developed clinical evidence of inflammation showed strong expression of CD4 and CD8 (data not shown). p53 Immunostaining correlated closely with histological evidence of dysplasia in imiquimod-treated skin (11 of 14) and not with clinical response (Figure 4).

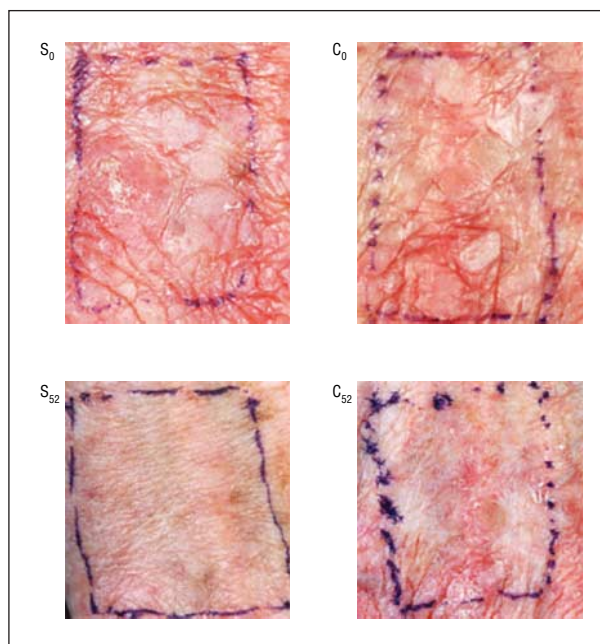


Figure 2. Clinical improvement in patient 1 in the number of warts, keratotic lesions, and skin quality in the study hand (S) compared with the control hand (C) between weeks 0 and 52.

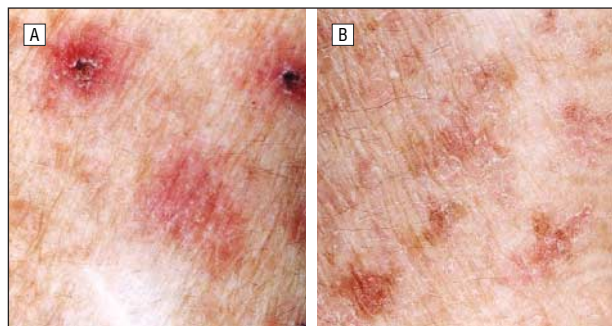


Figure 3. Inflammation in patient 5 on the study hand (A) compared with the control hand (B) determined clinically after applying 5% imiquimod cream 3 times per week for 16 weeks.

Table 3. Cutaneous SCC Development in the Study and Control Skin Areas in 12 Months

Patient Group and No.	Study Site (Treated With 5% Imiquimod Cream or Placebo)	Control Site (Untreated)
Imiquimod-treated patients (n = 14)		
8	None	SCC @ 6 mo
10	None	CIS @ 9 mo
16*	CIS @ 8 mo CIS @ 12 mo	CIS @ 4 mo
22	None	SCC @ 4 mo
Placebo-treated patients (n = 6)		
7	SCC @ 8 mo	None
18	SCC @ 4 mo	SCC @ 9 mo
21	None	SCC @ 10 mo

Abbreviations: CIS, carcinoma in situ; SCC, squamous cell carcinoma.

*Patient 16 was receiving systemic retinoids.

COMMENT

We report the outcome of the first randomized, double-blind, placebo-controlled trial of 5% imiquimod cream in immunosuppressed organ transplant recipients. The primary objective of this study was to evaluate the safety and efficacy of this topical immunostimulatory agent in the treatment of cutaneous dysplasia in high-risk individuals. A secondary objective was to review the development of SCC or CIS in imiquimod-treated areas during 1 year of follow-up.

Our study design included a left-right within-patient comparison to reduce possible confounding effects between patients, such as number of, type of, and length of time taking immunosuppressant drugs; level of immunosuppression; age; skin type; and previous sun exposure, all of which affect skin cancer risk. Although systemic absorption of study drug might theoretically invalidate such a study design, we believed that this was unlikely given the small treatment areas used and available pharmacokinetic data demonstrating insignificant systemic absorption of topically administered imiquimod.²⁶ Similarly, although there is a theoretical risk of allograft rejection because imiquimod will increase interferon levels, we believed that it was possible to treat

small areas of skin safely in these patients while maintaining systemic immunosuppression and monitoring graft function.

SAFETY AND TOLERABILITY IN IMMUNOSUPPRESSED PATIENTS

Our data suggest that 5% imiquimod cream is safe to use 3 times per week on up to 60-cm² areas of skin in RTRs and is generally well tolerated. Five of 14 imiquimod-treated patients developed local inflammatory symptoms. These symptoms occurred less frequently and started later (weeks 4-16) than is usually seen in studies of immunocompetent people. For example, in a double-blind study¹² of AKs, 100% of the patients who used imiquimod experienced mild, moderate, or severe reactions starting in week 2 and peaking in week 6. In another study⁶ of superficial BCCs, imiquimod treatment resulted in signs of erosion after 3 to 5 days in 5 of 6 immunocompetent patients. The delayed response in our immunosuppressed patients has previously been observed in RTR-treated perianal warts²⁷ and may reflect a failure to recruit the effector cells needed to stimulate the cutaneous immune system of immunosuppressed individuals (see the following subsection).

Graft function was unaffected by the use of imiquimod in this study. Although 2 patients (9.5%) died during the study, this mortality rate was no different from that of 8.6% seen in the renal transplant skin clinic cohort as a whole during the same period. Both patients who died were using active cream, but this could not be implicated in the cause of death.

EFFECTIVENESS OF IMIQUIMOD IN IMMUNOSUPPRESSED PATIENTS

Of the 14 patients using active cream, 7 (50%) demonstrated a reduction in skin atypia and plane VWs in the treatment area compared with 1 (17%) of 6 patients who received placebo ($P = .32$). However, only 5 (36%) of 14 patients treated with imiquimod demonstrated a reduction in the number of AKs at the end of treatment, in contrast to the 84% of patients who experienced total clearance of all AKs in a double-blind, placebo-controlled study conducted in immunocompetent individuals by Stockfleth and colleagues.¹²

There could be several explanations for this apparent discrepancy, including the failure to recruit effector cells. Systemic immunosuppressive therapy reduces T-cell function, dendritic cell trafficking, and macrophage activation, and an increased dose of imiquimod may be required for an equivalent inflammatory response. The 3-times-weekly dosing regimen used in this study was documented to be effective for the treatment of genital warts in immunocompetent individuals⁷ but may have been insufficient for treating epidermal sites in transplant recipients. Alternatively, if RTRs are profoundly immunosuppressed, imiquimod may be unable to modulate innate and acquired cellular immune responses even with higher dosing regimens. A site-specific difference in the inflammation produced with imiquimod on dorsal hand skin compared with forehead skin is another possible expla-

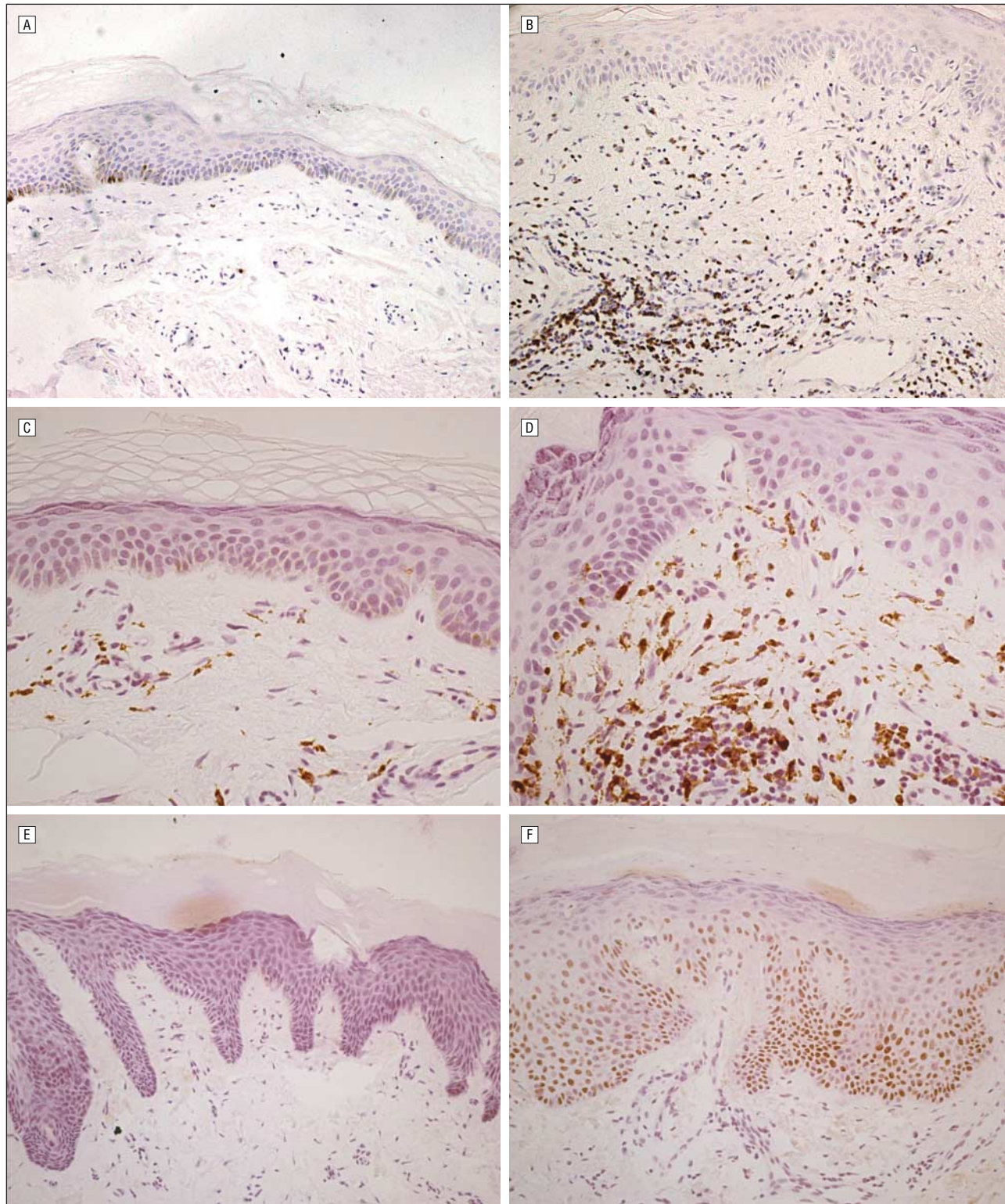


Figure 4. Biopsy samples from control skin (A, C, and E) and 5% imiquimod cream–treated skin (B, D, and F) collected at week 16 in patient 4 (A–D) and patient 2 (E and F). Immunohistochemical expression is shown for CD8 (A and B; original magnification $\times 100$), CD68 (C and D; original magnification $\times 200$), and p53 (E and F; original magnification $\times 100$).

nation and is supported by anecdotal observations in the immunocompetent population. These factors may have contributed to the variable results and the relatively few patients who developed clinical evidence of skin inflammation in this study. Although an influx of CD68-

expressing macrophages was demonstrated in 9 of 14 imiquimod-treated patients, our data suggest that more intense treatment regimens, possibly with occlusion, should be considered in immunosuppressed individuals. More aggressive dosage regimens of 5 to 7 applica-

tions per week have been shown to be optimal for the treatment of BCCs in immunocompetent people, and it has been noted that increasing severity of erythema, erosion, and scabbing/crusting is associated with higher clearance rates.⁹

CHEMOPROPHYLACTIC EFFICACY OF IMIQUIMOD AND INTERACTION WITH SYSTEMIC RETINOIDS

Only 1 of the 14 imiquimod-treated patients developed histologically confirmed CIS in the imiquimod-treated area of skin during follow-up of the 1-year study. He, along with 6 other patients, also developed CIS or invasive SCC in the control or placebo-treated areas of skin. These data emphasize the high-risk nature of RTRs, making them an ideal population in which to assess a potential chemoprevention role for imiquimod. Our data suggest a possible reduction in squamous malignancies in imiquimod-treated skin, although this was not statistically significant, perhaps because of small patient numbers. Nonetheless, these results suggest that further studies treating larger skin areas in a larger number of patients are now justified.

We intentionally included several patients receiving low-dose systemic retinoids in this study because in our specialist organ transplant dermatology clinic many high-risk patients with multiple nonmelanoma skin cancers receive acitretin as part of a chemoprophylactic strategy.²⁸ Within the limitations of this small study, we found no difference in response to imiquimod in retinoid-treated patients compared with patients who were not taking this treatment.

STUDY LIMITATIONS

This study has several limitations, although it remains the largest controlled trial in RTRs to date, to our knowledge. First, small patient numbers reduced the power to confirm the apparent positive benefit of imiquimod. This may have been compounded by the small size of the treatment areas. However, until the safety data have accumulated, it would seem unwise to treat large skin areas in this allograft population. Second, the relative level of immunosuppression is likely to differ in individual RTRs and is difficult to compare. In the absence of a reliable measure of immunosuppression level, all RTRs are taking standard doses of 2 to 4 immunosuppressive drugs. Thus, we could not control for the degree of immunosuppression in individuals randomized to the active vs placebo arms, and it seems probable that the imiquimod dosing regimen was inadequate for some patients. The few patients who developed a clinically notable inflammatory response would support this supposition. Third, it is expected that the biopsy findings for dysplasia in treatment and control sites may be liable to sample bias. Great care was taken to choose equivalent areas of clinically atypical skin at the start of the study for week 16 biopsy sampling. However, clinical assessment of skin atypia will not necessarily predict histological dysplasia. This may explain why there was good, but not complete, correlation between clinical and histological assessments (Table 2).

CONCLUSIONS

To our knowledge, this is the first randomized controlled trial of imiquimod for the treatment of cutaneous premalignancy in organ transplant recipients. The accelerated skin carcinogenesis seen in RTRs makes them the ideal population in which to evaluate the potential of topical immunostimulatory agents for chemoprevention. There are reports of studies treating cutaneous VWs in immunosuppressed patients,^{20,21,29} but none other than case reports or small open series examining the treatment of squamous malignancy in transplant recipients.^{24,30} Our study adds to these published articles because it is larger and incorporates a randomized, double-blind, and placebo-controlled study design. The apparent benefit of imiquimod in this study requires confirmation with a larger study population treating more extensive areas of diseased skin, perhaps under occlusion or after pretreatment with keratolytics. It remains to be seen whether imiquimod will be the agent used to arrest the ever-increasing burden of cutaneous neoplastic and infectious complications that result from long-term immunosuppression.

Accepted for Publication: March 9, 2005.

Correspondence: Charlotte M. Proby, MA, FRCP, Centre for Cutaneous Research, 2, Newark St, Whitechapel, London E1 2AT, England (charlotte.proby@cancer.org.uk).

Funding/Support: This investigator-initiated study was supported by 3M Health Care Ltd, who supplied imiquimod and placebo cream, funded research nurse time, and paid for patients' travel expenses. Drs Harwood, Ghali, and Proby received grant support from Cancer Research UK.

Additional Information: Dr Brown is a Medical Research Council Training Fellow.

REFERENCES

1. Berg D, Otley CC. Skin cancer in organ transplant recipients: epidemiology, pathogenesis, and management. *J Am Acad Dermatol.* 2002;47:1-20.
2. Hemmi H, Kaisho T, Takeuchi O, et al. Small anti-viral compounds activate immune cells via the TLR7/MyD88-dependent signaling pathway. *Nat Immunol.* 2002;3:196-200.
3. Stanley MA. Imiquimod and the imidazoquinolones: mechanism of action and therapeutic potential. *Clin Exp Dermatol.* 2002;27:571-577.
4. Arany I, Tyring SK, Brysk MM, et al. Correlation between pretreatment levels of interferon response genes and clinical responses to an immune response modifier (Imiquimod) in genital warts. *Antimicrob Agents Chemother.* 2000;44:1869-1873.
5. Schon M, Bong AB, Drewniok C, et al. Tumor-selective induction of apoptosis and the small-molecule immune response modifier imiquimod. *J Natl Cancer Inst.* 2003;95:1138-1149.
6. Uroseevic M, Maier T, Benninghoff B, Slade H, Burg G, Dummer R. Mechanisms underlying imiquimod-induced regression of basal cell carcinoma in vivo. *Arch Dermatol.* 2003;139:1325-1332.
7. Edwards L, Ferenczy A, Eron L, et al. Self-administered topical 5% imiquimod cream for external anogenital warts: HPV Study Group. *Arch Dermatol.* 1998;134:25-30.
8. Sterry W, Ruzicka T, Herrera E, et al. Imiquimod 5% cream for the treatment of superficial and nodular basal cell carcinoma: randomized studies comparing low-frequency dosing with and without occlusion. *Br J Dermatol.* 2002;147:1227-1236.
9. Geisse J, Caro I, Lindholm J, Golitz L, Stampone P, Owens M. Imiquimod 5%

- cream for the treatment of superficial basal cell carcinoma: results from two phase III, randomized, vehicle-controlled studies. *J Am Acad Dermatol.* 2004;50:722-733.
10. Marks R, Owens M, Walters SA. Efficacy and safety of 5% imiquimod cream in treating patients with multiple superficial basal cell carcinomas. *Arch Dermatol.* 2004;140:1284-1285.
 11. Hengge UR, Esser S, Schultewolter T, et al. Self-administered topical 5% imiquimod for the treatment of common warts and molluscum contagiosum. *Br J Dermatol.* 2000;143:1026-1031.
 12. Stockfleth E, Meyer T, Benninghoff B, et al. A randomized, double-blind, vehicle-controlled study to assess 5% imiquimod cream for the treatment of multiple actinic keratoses. *Arch Dermatol.* 2002;138:1498-1502.
 13. Persaud AN, Shamuelova E, Sherer D, et al. Clinical effect of imiquimod 5% cream in the treatment of actinic keratosis. *J Am Acad Dermatol.* 2002;47:553-556.
 14. Mackenzie-Wood A, Kossard S, de Launey J, Wilkinson B, Owens ML. Imiquimod 5% cream in the treatment of Bowen's disease. *J Am Acad Dermatol.* 2001;44:462-470.
 15. Hengge UR, Schaller J. Successful treatment of invasive squamous cell carcinoma using topical imiquimod. *Arch Dermatol.* 2004;140:404-406.
 16. Florez A, Feal C, de la Torre C, Cruces M. Invasive squamous cell carcinoma treated with imiquimod 5% cream. *Acta Derm Venereol.* 2004;84:227-228.
 17. Harwood CA, Proby CM. Human papillomaviruses and non-melanoma skin cancer. *Curr Opin Infect Dis.* 2002;15:101-114.
 18. Benson E. Imiquimod: potential risk of an immunostimulant. *Australas J Dermatol.* 2004;45:123-124.
 19. Dupin N, Soubrane O, Escande JP. Partial efficacy of imiquimod on plantar warts in immunodeficient patients [in French]. *Ann Dermatol Venereol.* 2003;130:210-211.
 20. Weisshaar E, Gollnick H. Potentiating effect of imiquimod in the treatment of verrucae vulgares in immunocompromised patients. *Acta Derm Venereol.* 2000;80:306-307.
 21. Harwood CA, Perrett CM, Proby CM, et al. Imiquimod cream 5% for recalcitrant cutaneous warts in immunosuppressed individuals. *Br J Dermatol.* 2005;152:122-129.
 22. Buckley R, Smith K. Topical imiquimod therapy for chronic giant molluscum contagiosum in a patient with advanced human immunodeficiency virus 1 disease. *Arch Dermatol.* 1999;135:1167-1169.
 23. Liota E, Smith KJ, Buckley R, Menon P, Skelton H. Imiquimod therapy for molluscum contagiosum. *J Cutan Med Surg.* 2000;4:76-82.
 24. Smith KJ, Germain M, Skelton H. Squamous cell carcinoma in situ (Bowen's disease) in renal transplant patients treated with 5% imiquimod and 5% 5-fluorouracil therapy. *Dermatol Surg.* 2001;27:561-564.
 25. Vidal D, Alomar A. Efficacy of imiquimod 5% cream for basal cell carcinoma in transplant patients. *Clin Exp Dermatol.* 2004;29:237-239.
 26. Owens ML, Bridson WE, Smith SL, Myers JA, Fox TL, Wells TM. Percutaneous penetration of Aldara cream, 5% during the topical treatment of genital and perianal warts. *Prim Care Update Ob Gyns.* 1998;5:151.
 27. Gayed SL. Topical imiquimod cream 5% for resistant perianal warts in a renal transplant patient. *Int J STD AIDS.* 2002;13:501-503.
 28. Harwood CA, Leedham-Green M, Leigh IM, Proby CM. Low-dose retinoids in the prevention of cutaneous squamous cell carcinomas in organ transplant recipients: a 16-year retrospective study. *Arch Dermatol.* 2005;141:456-464.
 29. Schmook T, Nindl I, Ulrich C, Meyer T, Sterry W, Stockfleth E. Viral warts in organ transplant recipients: new aspects in therapy. *Br J Dermatol.* 2003;149(suppl 66):20-24.
 30. Prinz BM, Hafner J, Dummer R, Burg G, Bruswanger U, Kempf W. Treatment of Bowen's disease with imiquimod 5% cream in transplant recipients. *Transplantation.* 2004;77:790-791.

ARCHIVES Web Quiz Winner

Congratulations to the winner of our May quiz, El-Shahat Farag Ahmed, MD, Assistant Professor of Dermatology, Dermatology Department, Mansoura Faculty of Medicine, Mansoura, Egypt. The correct answer to our May challenge was *Papillon-Lefevre syndrome*. For a complete discussion of this case, see the "Off-Center Fold" section in the June ARCHIVES (Georgala S, Befon A, Georgala C. Psoriasiform plaques and periodontal infection. *Arch Dermatol.* 2005;141:779).

Be sure to visit the *Archives of Dermatology* Web site (<http://www.archdermatol.com>) to try your hand at the interactive quiz. We invite visitors to make a diagnosis based on selected information from a case report or other feature scheduled to be published in the following month's print edition of the ARCHIVES. The first visitor to e-mail our Web editors with the correct answer will be recognized in the print journal and on our Web site and will also receive a free copy of *The Art of JAMA II*.