

Skin Cancer in Organ Transplant Recipients—Where Do We Stand Today?

C. Ulrich^a, J. Kanitakis^b, E. Stockfleth^a
and S. Euvrard^{b,*}

^aDepartment of Dermatology, Charité
Universitätsmedizin, Berlin, Germany and ^bDepartment of
Dermatology, Hôpital Edouard Herriot, Lyon, France

*Corresponding author: Sylvie Euvrard,
sylvie.euvrard@numericable.fr

Skin cancers are the most frequent malignancies in organ transplant recipients (OTR), with 95% being non-melanoma skin cancers (NMSC), especially squamous (SCC) and basal cell carcinomas. Most OTR with a first SCC subsequently develop multiple NMSC within 5 years, highlighting the concept of 'field cancerization', and are also at high risk for noncutaneous cancers. In order to reduce the tumor burden in these patients, their management requires an interdisciplinary approach including revision of immunosuppression, new dermatological treatments and adequate education about photoprotection in specialized dermatology clinics for OTR. Whereas surgery remains the gold-standard therapy for NMSC, noninvasive methods have shown promising results to treat superficial keratoses and subclinical lesions on large body areas. Although the threshold of skin cancer necessitating revision of immunosuppression is debated, this measure should be envisaged at the occurrence of the first SCC, or in case of multiple non-SCC NMSC. While the role of immunosuppressants in the occurrence of NMSC is widely recognized, the best immunosuppressive strategies remain to be defined. Presently, randomized prospective studies assess the burden of new skin tumors, as well as graft and patient survival, in patients with one or several NMSC after the introduction of mTOR (mammalian target of rapamycin) inhibitors.

Key words: Immunosuppression, mTOR inhibitors, organ transplantation, skin cancer prophylaxis, skin cancer treatment, sun-screen

Received 08 April 2008, revised 03 July 2008 and accepted for publication 16 July 2008

Introduction

Skin cancers are the most frequent malignancies after organ transplantation (1,2). Although the incidence of some rare tumors (such as melanoma, Merkel cell carcinoma

and Kaposi's sarcoma) is also increased compared with the general population, this paper will focus on NMSC, especially squamous cell carcinomas (SCC) and basal cell carcinomas (BCC), which account for 95% of the skin cancers in organ transplant recipients (OTR). The management of OTR with skin cancers requires an interdisciplinary approach. This article reviews the latest data concerning the epidemiologic, pathogenic and therapeutic aspects of nonmelanoma skin cancers (NMSC) in kidney (KTR), heart (HTR) and liver (LTR) transplant recipients, and also presents running prospective randomized studies concerning new immunosuppressive strategies to face the challenge of posttransplant NMSC.

Epidemiology

The incidence of NMSC increases steadily with time after transplantation and varies in the United States and Western Europe from 5% to 10–27% to 40–60% at 2, 10 and 20 years, respectively (3–5). Higher figures are observed in Australia, where the 20 years incidence reaches 70–82%. Several studies have shown a 2- to 4-fold higher incidence in HTR as compared with KTR (2,6,7). Studies on skin cancers in LTR are more scarce (2,8); current data suggest that their incidence could be similar to KTR (7,8).

In OTR the ratio of SCC to BCC (4/1) is reversed compared with the population at large, and this reversal increases with decreasing latitude, sun exposure and length of follow-up (1,2). While age-matched KTR and HTR show similar ratios, LTR seem to have a higher rate of BCC.

Clinical features

SCC and BCC appear on sun-exposed areas after a mean interval of 8 to 10 years after transplantation. They are often associated with multiple keratotic lesions and other skin tumors that mimic clinically invasive SCC, such as actinic keratoses (AK), Bowen's disease (*in situ*, SCC) and keratoacanthoma. Keratotic skin lesions were recently defined in a consensus meeting and consist of warty/verrucous lesions whose clinical diagnosis is difficult. They may correspond to actinic keratoses, seborrheic keratoses/warts, flat warts and papillomas (9). Multiple keratotic skin lesions were shown to be associated with an increased risk of SCC, with 4-fold and 12-fold elevated risk in cases of ≤ 49 and ≥ 50 lesions, respectively, compared with patients devoid of such lesions (9). All these lesions correspond to extensive areas

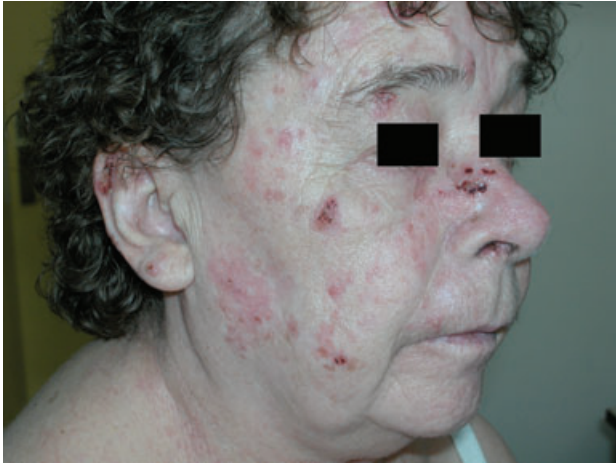

Figure 1: An example of field cancerization: Multiple non-melanoma skin cancers on the face of a renal transplant recipient.

of actinic damage including visible and subclinical lesions of epidermal dysplasia and highlight the concept of field cancerization (Figure 1).

Recent data suggest that the occurrence of NMSC should be given consideration as early as possible. Indeed, in a study of nearly 200 KTR and HTR with SCC, the first SCC was shown to be predictive of subsequent multiple NMSC, since 100% of HTR and 88% of KTR developed multiple new tumors within the 5 years following the first SCC (10).

SCC seem to be more aggressive, may grow rapidly, recur locally in 13.4% of patients and metastasize in 5–8% of them. However, the rate of deaths specifically related to SCC is not precisely known. Furthermore, a 18.6% rate of extracutaneous tumors was recently reported in patients with SCC, thus confirming previous results showing that OTR with skin cancers had more second primary cancers than those without (11). This is in keeping with the finding that SCC is the tumor associated with the highest risk for a second primary cancer in men.

Risk Factors

Whereas OTR share similar determinants with immunocompetent individuals, their specific tumor burden appears to be linked to the type, dosage and duration of immunosuppression. The most important predisposing factors include fair color of the skin, eyes and hair and susceptibility to sunburn. Cumulative ultraviolet radiation (especially UVB) is the primary responsible carcinogen for the induction of NMSC, as suggested by the fact that the lesions almost exclusively appear on UV-exposed skin sites and are more numerous in patients living in sunny countries; however, it was recently shown that even after the first SCC,

the rate of subsequent NMSC can be decreased if patients change their behavior and protect themselves from the sun (10).

Age is also an important risk factor: in both KTR and HTR, the risk ratio was reported to be 12-fold higher in patients receiving grafts beyond age 55, compared to patients with grafts received before the age of 34 (7). While the higher prevalence of NMSC in HTR has long been thought to be due to greater immunosuppression, it seems that the older age of HTR at transplantation is the main reason (2,6,7). Indeed, the dosages of immunosuppressants in HTR and KTR at the occurrence of skin cancer were recently found to be similar (10).

Duration of immunosuppression seems to intervene on the multiplicity of lesions since the number of lesions per patient over the same follow-up period is significantly higher in KTR versus HTR (10). This could be due to the younger age at transplantation of KTR, who have a longer exposure to immunosuppression at the occurrence of the first SCC. Patients older at transplantation, even if they develop the first SCC sooner, have a shorter immunosuppression time at the first NMSC and are more similar to the general population.

Further risk factors include history of skin cancer prior to transplantation, male sex and various genetic factors such as polymorphisms in glutathione S-transferase, interleukin 10, the folate pathway, vitamin D receptor genes, several of them being possibly related to skin type (12). Among them, the p53 tumor suppressor gene is the most frequently mutated in skin cancers. Mutations of p53 have been detected immunohistochemically as p53 patches in normal-looking skin in OTR. The frequency of these patches, which represent microscopic precursors of SCC, can serve as a good marker for SCC risk (13) and supports the concept of 'field cancerization'. There is some evidence suggesting that pre-transplant disease may influence the risk of posttransplant NMSC but conclusive studies are limited. Skin cancer risk was found to be decreased in KTR with diabetes and increased in KTR with polycystic kidney disease (3,7,14) and in LTR with cholestatic liver diseases and cirrhosis (7,8).

The favoring role of various factors including dialysis, smoking and alcohol is still debated (8,9). Human papillomavirus infections are obviously associated with an increased risk of skin cancer, although their mechanism of action remains under intense investigation.

Role of immunosuppressive agents

The role of immunosuppressive treatment in the occurrence of NMSC is widely recognized. Skin cancers result both from a decrease in immunosurveillance and from the direct oncogenic effects linked to some immunosuppressants (15), although it is difficult to know which mechanism

predominates. The incidence of NMSC has been shown to be proportional to the level of immunosuppression, as CD4 counts are significantly lower in OTR with NMSC versus those patients without such malignancies. An indirect evidence of immunosuppressive load is the higher risk of skin cancer in patients with poor renal function (serum creatinine levels at 1 year >150 $\mu\text{mol/L}$) who require higher immunosuppression, and the lower risk in patients with a living donor (5) who generally receive less immunosuppression. In several studies, patients receiving triple immunosuppression (cyclosporine [CsA], corticosteroids and azathioprine or sirolimus [SRL]) were found to have a three-fold increased risk for NMSC, as compared with patients taking two immunosuppressants (corticosteroids and azathioprine or SRL) (1,16,17). A 5-year prospective study showed that low-dose CsA regimens were associated with a lower incidence of tumors than was standard therapy (11). The effect of immunosuppression seems to be reversible since a decrease in new tumor development has been reported after reduction or cessation of immunosuppression in patients who return to dialysis, in those with aggressive SCC or those who have a first SCC (10,16). The increased risk of acute rejection linked to the reduction of immunosuppressants is difficult to assess because the degree of immunosuppression may be different with similar drug dosages, depending on patients' individual sensitivity.

The results of several studies suggest that calcineurin inhibitors (CNI) have oncogenic properties mainly linked to the production of cytokines that promote tumor growth, metastasis and angiogenesis (15). By contrast, mTOR inhibitors (mammalian target of rapamycin) including mainly SRL and everolimus, may have antitumoral properties by blocking angiogenesis. Most of these studies have been performed on nonskin tumors and are reviewed in another article, therefore, we will focus here on aspects related specifically to skin cancers. The interaction of UV with different immunosuppressants has recently gained specific attention. Azathioprine sensitizes cells to UVA-induced damage. The active metabolite of azathioprine is incorporated into cellular DNA and has been shown to generate mutagenic reactive oxygen species when exposed to UVA light (18). Foci of epidermal cells expressing mutant p53 were found more prevalent in KTR under azathioprine than in immunocompetent patients in normal skin adjacent to carcinomas (13). Recent studies have assessed the influence of 'never-age' immunosuppressants in various combinations on UVB-induced skin carcinogenesis (19,20). Mice treated with CsA or Tacrolimus (TAC) developed larger tumors than vehicle-treated mice. Malignant tumors were the most prevalent tumors in CsA-treated animals. Mycophenolate mofetil (MMF) treatment alone had no effect on tumor number or size. The addition of MMF to CsA, but not to TAC, significantly reduced tumor size. Although mice treated with SRL alone or in combination with CsA or TAC developed more skin tumors than those treated with vehicle or other immunosuppressants, the tumors were significantly smaller. In this same study,

SRL was shown to reduce tumor size through effects on inflammation and angiogenesis (19).

Prospective clinical studies suggest that mTOR inhibitors could have a preventive action on cancerogenesis; indeed, KTR treated *de novo* with these molecules had a lower incidence of malignancies, especially cutaneous ones, as compared with those treated with CNIs (14,17,21). These antitumoral properties reportedly manifested also after the occurrence of cutaneous malignancies. A striking example is provided by a KTR with Muir-Torre syndrome in whom the administration of a TAC-based regimen led to the eruption of multiple sebaceous tumors. Conversion to a SRL-based regimen resulted in tumor regression. Because of SRL side effects, the patient was switched back to TAC and new facial lesions rapidly appeared; reconversion to SRL again halted the appearance of additional lesions (22). However, it is mainly in the setting of posttransplant Kaposi's sarcoma where switch to mTOR inhibitors has been assessed. The first studies reported regression of Kaposi's sarcoma after switch to SRL, although this course might have been favored by the withdrawal of other immunosuppressants. Additional data with a longer follow-up have shown that Kaposi's sarcoma may relapse under SRL; besides, some patients are nonresponders (23). Drug resistance may develop due to acquired mutations to mTOR or FKBP12, preventing SRL from binding to mTOR; alternatively, tumor cell proliferation could become dependant on other molecular pathways. This may explain why three Kaposi's sarcoma patients of this series (23) experienced cancer onset or progression (including primary effusion lymphoma, lung and breast cancers) while receiving SRL.

Conversion to mTOR inhibitors has also been reported in small noncontrolled studies of KTR with NMSC (24,25). The number of new skin tumors was found to decrease, but the follow-up was short.

Treatment (Table 1)

The management of NMSC depends on the type and the numbers of lesions (Table 1). In all OTR with suspected or biopsy-proven invasive SCC and BCC, surgery with histology-controlled margins is the gold-standard therapy. Whereas full body examination is mandatory in all dermatological checkups, it necessarily includes examination for cutaneous satellite lesions and palpation of draining lymph nodes in OTR with SCC (26).

The areas of 'field cancerization' account for a vast majority of the NMSC-related morbidity and mortality and have become the key target of most dermatological initiatives to reduce the skin cancer burden in OTR (27). The most important clinical implication is that unspecific destructive therapies of individual primary lesions with surgery, cryotherapy, curettage or laser do not usually prevent the occurrence of new cancers or of local recurrences.

Table 1: A scheme for the management of nonmelanoma skin cancers in organ transplant recipients

Actinic keratosis	Management	Invasive squamous cell carcinoma	Management	Basal cell carcinoma	Management
Mild (< 5 AK)	<ul style="list-style-type: none"> - Sunprotective measures - Lesion-adapted destructive therapies • Cryotherapy • CO2 laser • Electrocautery/ Curettage - Consider field-adapted therapies 	Clinically less aggressive <ul style="list-style-type: none"> • Small size • Slow growing • Well-defined margins • Nonulcerated 	<ul style="list-style-type: none"> - Sunprotective measures - Treatment of field cancerization - Complete removal (consider Mohs' micrographic surgery) - Systemic therapies Revision of immunosuppression 	Superficial (sBCC)	<ul style="list-style-type: none"> - Sunprotective measures - Therapies for superficial BCC • 5-Fluorouracil • 5% Imiquimod cream • Photodynamic therapy - Complete removal (consider Mohs' micrographic surgery)
Moderate (> 5 AK in < 100 cm ² area)	<i>See above plus:</i> <ul style="list-style-type: none"> - Field cancerization therapies • 3% diclofenac in 2.5% hyaluronic acid gel • 5% Imiquimod cream • 5-Fluorouracil • Photodynamic therapy - Consider revision of immunosuppression 	Clinically aggressive <ul style="list-style-type: none"> • Large size + location • Rapid growth • Poorly defined margins • Ulcerated 	<i>See above plus:</i> <ul style="list-style-type: none"> - Consider sentinel lymph node biopsy ± dissection - Consider systemic retinoids 	Nodular and other non sBCC	<i>See above plus:</i> <ul style="list-style-type: none"> - Consider revision of immunosuppression
Severe (> 15 AK / > 100 cm ²)	<i>See above plus:</i> <ul style="list-style-type: none"> - Systemic therapies • Revision of immunosuppression • Systemic retinoids 	Histologically aggressive <ul style="list-style-type: none"> • Poorly differentiated • Invading subcutaneous fat • Perineural invasion 	<i>See above plus:</i> <ul style="list-style-type: none"> - Sentinel lymph node biopsy ± dissection - Consider systemic retinoids 		

This leads to a repetitive and often frustrating cycle of destructive treatments. Since immunosuppressed patients have a highly accelerated rate of AK development and progression into invasive SCC, those management strategies that counteract the effects of systemic immunosuppression (via the induction of a locally restricted tumor-specific immune response, the induction of apoptosis in dysplastic keratinocytes or the use of phototoxic agents) provide the advantage of treating large clinical and subclinical lesions in UV-exposed areas. Topically applied imiquimod, 5-fluorouracil, photodynamic therapy and 3% diclofenac gel are promising noninvasive alternative treatment modalities applicable to larger treatment areas (27–30). Systemic retinoids (initially etretinate that has been replaced by its active metabolite, acitretin) can be used for chemoprevention of NMSC in OTR since they reduce the number of preexisting AK and slowdown the development of new lesions. Their effect is only exerted during therapy and long-term use may be limited by side effects. The treatment should be started at a low dose (10 mg daily that can be increased to 30 mg), and patients should be monitored for serum triglycerids, cholesterol and transaminase levels. Topical retinoids (mainly tretinoin) reduces actinic keratoses and can be given alone or in association with acitretin (31).

New Immunosuppressive Strategies for Skin Cancer

Immunosuppression revision is widely accepted for Kaposi's sarcoma, but is more debated for NMSC. On the other hand, there are currently no guidelines available defining which threshold of cancer development necessitates modification of immunosuppression. However, it seems reasonable to consider revision of immunosuppression as an adjuvant therapeutic option not only in patients with multiple and/or aggressive SCC, but also at the occurrence of the first SCC because of the high rate of subsequent NMSC and other nonskin cancers. This could also be discussed for patients who have not yet had SCC, but who have developed multiple AK, Bowen's disease or BCC. The best way to reduce immunosuppression ('minimization') in OTR with NMSC is also a matter of discussion; in a retrospective study, changing one or several drugs in various regimens led to 24 different patterns of minimization (10). Considering that reduction of immunosuppression is associated with a lower incidence of skin cancer (and a higher risk for rejection), together with reports suggesting SRL may be associated with less skin cancers, the current challenge is to determine if conversion to mTOR inhibitors is a better option than minimization for patients with NMSC.

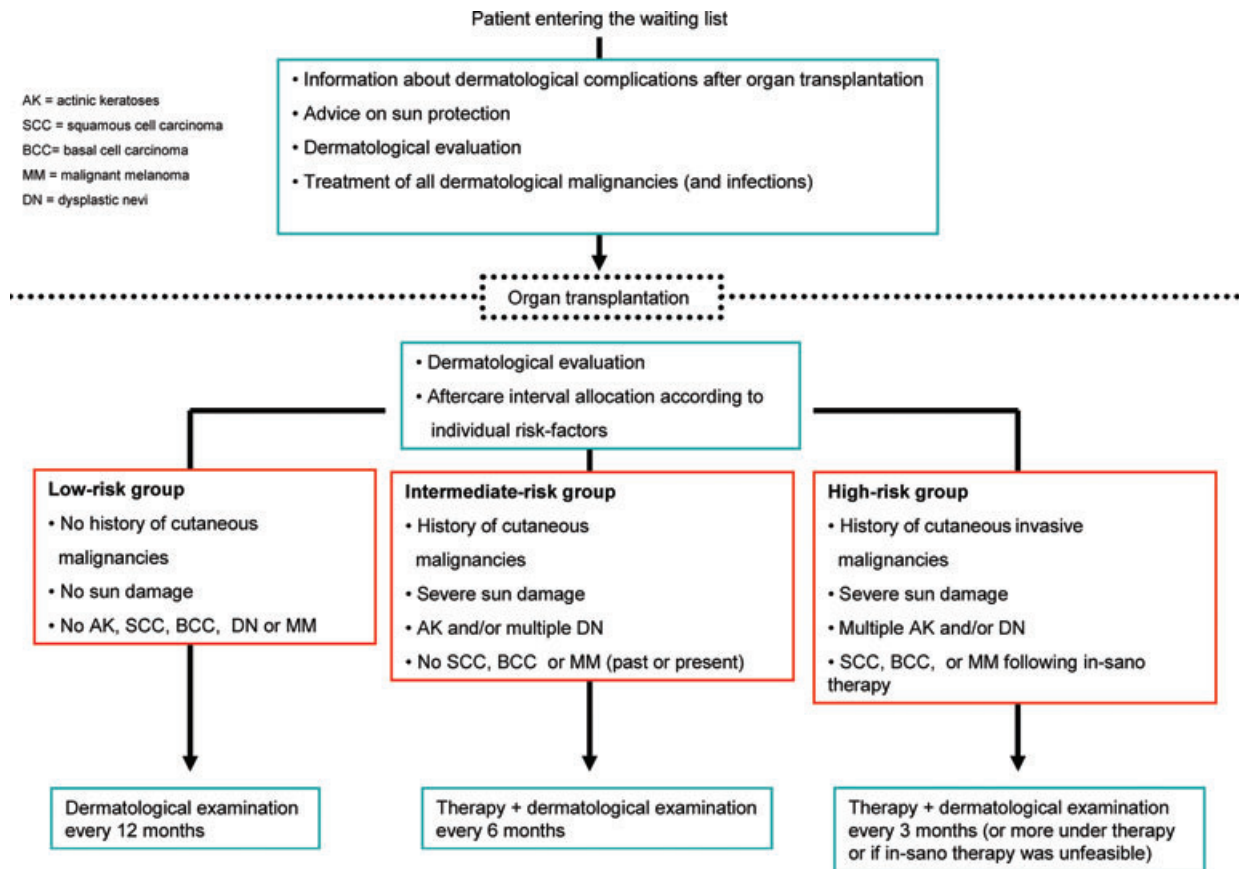


Figure 2: A scheme for dermatological evaluation and aftercare in organ transplant recipients.

These promising results could be hampered by SRL side effects that seem to be more frequent when SRL is given to patients immunosuppressed for several years. Mucocutaneous side effects (including mainly edema and mouth ulcers) are frequent (32) and may lead to SRL discontinuation.

Several statistically powered randomized prospective trials are ongoing for testing the potential antineoplastic effects of mTOR inhibitors on NMSC in OTR (www.clinicaltrials.gov). The TUMORAPA trials include patients with one or several SCC and compare one arm maintained under CNIs with a second arm where SRL substitutes for CNIs. In both groups the dosages of immunosuppressants are tapered to moderate levels. The RESCUE study also recruits patients with SCC, including those either under or not CNIs, and compares patients maintaining their initial treatment with those taking only corticosteroids and SRL. The PROSKIN trial, and the NCT00129961 studies also include patients with various and precocious NMSC, including AK and Bowen’s disease. Whereas most trials completely discontinue CNIs in the test arm, the PROSKIN study also allows a combination of SRL with previously applied CNIs in a reduced 50% dosage. New studies using everolimus have also been initiated in France and Germany

for HTR with NMSC. Of note, all the aforementioned studies assess the burden of new skin tumors, as well as graft and patient survival, over at least 2 years.

Prevention

All candidates for transplantation should receive a skin cancer risk factor-oriented assessment before entering the transplant waiting list. Posttransplant aftercare should be individually adjusted to prevalent extrinsic and intrinsic risk factors and must include oral and written information on skin cancer prevention, detection and treatment modalities (Figure 2). In order to reduce the risk of progression into invasive SCC, we recommend that all AK should be treated. Following strong evidence of subsequent skin cancers, the first SCC serves also as a predictive marker for multifocal tumor development and defines high-risk patients (10).

OTR have the possibility to reduce their NMSC risk by avoiding sun exposure, through sun-protective clothing and the use of sunscreens. However, due to various reasons including cost (sunscreens are generally not reimbursed by health insurance systems) and dislike for sunscreens (greasy, whitening effect, impractical in a work

environment), OTR are poorly compliant with their use. Modern sunscreens combining high protection and cosmetic acceptance offer a new alternative. A recent case-control study showed a decrease of AK in a patient group that was provided with a low-fat liposomal sunscreen giving a high protection level for UVA and UVB. No new invasive SCC occurred in the sunscreen group, while the patient group not supplied free sunscreen showed an increased incidence of AK and invasive SCC over the same period (33). Education about skin cancer risk, and compliance with photoprotective measures, have indeed improved with proper dissemination of information in specialized dermatology clinics for OTR (34). Undoubtedly, reducing skin cancer in OTR will depend on better patient education and improved coordination with dermatologic clinics.

Acknowledgment

C. Ulrich, E. Stockfleth have received research grants and are/were members of the speaker's bureau of Wyeth, Novartis, Hoffmann LaRoche, Meda, Almeral, Galderma, Spirig and Graceway. Jean Kanitakis is member of the speaker's bureau of Meda, and Sylvie Euvrard has received consultant and speaker honoraria from Wyeth and Novartis.

References

- Euvrard S, Kanitakis J, Claudy A. Skin cancers after organ transplantation. *N Engl J Med* 2003; 348: 1681–1691.
- Ulrich C, Schmook T, Sachse M, Sterry W, Stockfleth E. Comparative epidemiology and pathogenic factors for nonmelanoma skin cancer in organ transplant patients. *Dermatol Surg* 2004; 30: 622–627.
- Kasiskø BL, Snyder JJ, Gilbertson DT, Wang C. Cancer after kidney transplantation in the United States. *Am J Transplant* 2004; 4: 905–913.
- Ramsay HM, Reece SM, Fryere AA, Smith AG, Harden PN. Seven-year prospective study of nonmelanoma skin cancer incidence in UK renal transplant recipients. *Transplantation* 2007; 84: 437–439.
- Bordea C, Wojnarowska F, Millard PR, Doll H, Welsh K, Morris PJ. Skin cancers in renal-transplant recipients occur more frequently than previously recognized in a temperate climate. *Transplantation* 2004; 77: 574–579.
- Fortina AB, Caforio AL, Piaserico S et al. Skin cancer in heart transplant recipients: Frequency and risk factor analysis. *J Heart Lung Transplant* 2000; 19: 249–255.
- Otley C, Cherikh WS, Salsche SJ, McBride MA, Christenson LJ, Kauffman HM. Skin cancer in organ transplant recipients: Effect of pretransplant end-organ disease. *J Am Acad Dermatol* 2005; 53: 783–790.
- Euvrard S, Kanitakis J. Skin cancers after liver transplantation: What to do? *J Hepatol* 2006; 44: 27–32.
- Bouwes-Bavinck JN, Euvrard S, Naldi L et al. Keratotic skin lesions and other risk factors are associated with skin cancer in organ-transplant recipients: A case-control study in The Netherlands, United Kingdom, Germany, France and Italy. *J Invest Dermatol* 2007; 127: 1647–1656.
- Euvrard S, Kanitakis J, Decullier E et al. Subsequent skin cancers in kidney and heart transplant recipients after the first squamous cell carcinoma. *Transplantation* 2006; 81: 1093–1100.
- Dantal J, Hourmant M, Cantarovich D et al. Effect of long-term immunosuppression in kidney-graft recipients on cancer incidence: Randomised comparison of two cyclosporin regimens. *Lancet* 1998; 351: 623–628.
- Laing ME, Kay E, Conlon P, Murphy GM. Genetic factors associated with skin cancer in renal transplant patients. *Photodermatol Photoimmunol Photomed* 2007; 23: 62–67.
- De Graaf YGL, Rebel H, Elghalbzouri A et al. More epidermal p53 patches adjacent to skin carcinomas in renal transplant recipients than in immunocompetent patients: The role of azathioprine. *Exp Dermatol* 2008; 17: 349–355.
- Kauffman HM, Cherikh WS, Cheng U et al. Maintenance immunosuppression with target-of-rapamycin inhibitors is associated with a reduced incidence of de novo malignancies. *Transplantation* 2005; 80: 883–889.
- Guba M, Graeb C, Jauch KW, Geissler EK. Pro- and anti-cancer effects of immunosuppressive agents used in organ transplantation. *Transplantation* 2004; 77: 1777–1782.
- Otley CC, Maragh SL. Reduction of immunosuppression for transplant associated skin cancer: Rationale and evidence of efficacy. *Dermatol Surg* 2005; 31: 163–168.
- Campistol JM, Eris J, Oberbauer R et al. Sirolimus therapy after early cyclosporine withdrawal reduces the risk for cancer in adult renal transplantation. *J Am Soc Nephrol* 2006; 17: 581–589.
- O'Donovan P, Perret CM, Zhang X et al. Azathioprine and UVA light generate mutagenic oxidative DNA damage. *Science* 2005; 309: 1871–1874.
- Duncan FJ, Wulff BC, Tober KL et al. Clinically relevant immunosuppressants influence UVB-induced tumor size through effects on inflammation and angiogenesis. *Am J Transplant* 2007; 7: 2693–2703.
- Wulff BC, Kusewitt DF, VanBuskirk AM et al. Sirolimus reduces the incidence and progression of UVB-induced skin cancer in SKH mice even with co-administration of cyclosporine. *J Invest Dermatol* 8 May 2008 (Epub ahead of print).
- Mathew T, Kreis H, Friend P. Two-year incidence of malignancy in sirolimus-treated renal transplant recipients: Results from five multicenter studies. *Clin Transplant* 2004; 18: 446–449.
- Levi Z, Hazazi R, Kedar-Barnes I et al. Switching from Tacrolimus to Sirolimus halts the appearance of new sebaceous neoplasms in Muir-Torre Syndrome. *Am J Transplant* 2007; 7: 476–479.
- Lebbé C, Euvrard S, Barrou B et al. Sirolimus conversion for patients with posttransplant Kaposi's sarcoma. *Am J Transplant* 2006; 6: 2164–2168.
- Tessmer CS, Magalhaes LV, Keitel E et al. Conversion to sirolimus in renal transplant recipients with skin cancer. *Transplantation* 2006; 82: 1792–1793.
- Fernandez A, Marcen R, Pascual J et al. Conversion from calcineurin inhibitors to everolimus in kidney transplant recipients with malignant neoplasia. *Transplant Proc* 2006; 38: 2453–2455.
- Stasko T, Brown MD, Carucci J et al. Guidelines for the management of squamous cell carcinoma in organ transplant recipients. *Dermatol Surg* 2004; 30: 642–650.
- Ulrich C, Hackethal M, Ulrich M et al. Treatment of multiple actinic keratoses with topical diclofenac 3% gel in organ transplant recipients: A series of six cases. *Br J Dermatol* 2007; 156 S3: 40–42.
- Ulrich, Bichel J, Euvrard S et al. Topical immunomodulation under systemic immunosuppression: Results of a multicentre, randomized, placebo-controlled safety and efficacy study of imiquimod 5% cream for the treatment of actinic keratoses in kidney, heart, and liver transplant recipients. *Br J Dermatol* 2007; 157S2: 25–31.

Skin Cancer in Organ Transplant Recipients

29. Perrett CM, McGregor JM, Warwick J et al. Treatment of post-transplant premalignant skin disease: A randomized inpatient comparative study of 5-fluorouracil cream and topical photodynamic therapy. *Br J Dermatol* 2007; 156: 320–328.
30. De Graaf YG, Kennedy C, Wolterbeek R, Collen AF, Willemze R, Bouwes Bavinck JN. Photodynamic therapy does not prevent cutaneous squamous-cell carcinoma in organ-transplant recipients: Results of a randomized-controlled trial. *J Invest Dermatol* 2006; 126: 569–574.
31. De Graaf YG, Euvrard S, Bouwes Bavinck JN. Systemic and topical retinoids in the management of skin cancer in organ transplant recipients. *Dermatol Surg* 2004; 30: 656–661.
32. Mahé E, Morelon E, Lechaton S et al. Cutaneous adverse events in renal transplant recipients receiving sirolimus-based therapy. *Transplantation* 2005; 79: 476–482.
33. Ulrich C, Degen A, Patel MJ et al. Sunscreens in organ transplant patients. *Nephrol Dial Transplant* 2008; 23: 1805–1808.
34. Ismail F, Mitchell L, Casabonne D et al. Specialist dermatology clinics for organ transplant recipients significantly improve photoprotection and levels of skin cancer awareness. *Br J Dermatol* 2006; 155: 916–925.